

10 Classification of Established Volkmann's Ischemic Contracture and the Program for Its Treatment

In spite of the advances made in preventive treatment of muscular ischemia at the forearm and hand, there still exist cases produced by many different causes and not only depending on the classical complications of supracondylar or forearm fractures in children or constricting plaster casts.

Muscular ischemia passes through different evolutive periods: *initial* (vascular crisis), *evolutive* (paralysis), and *final*, or *established, contractures*. We will here refer to the established period only. The classification of the established ischemic contracture and the general program of correction will be based on the condition of the intrinsic muscles.

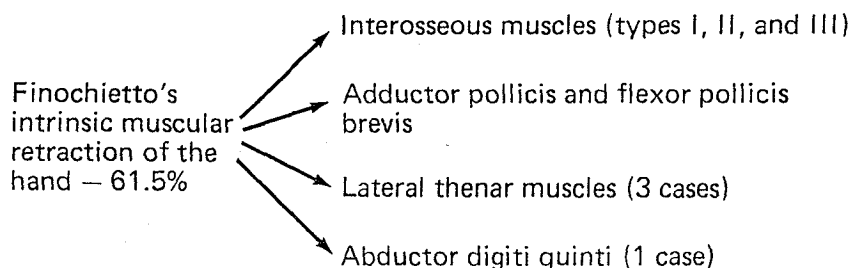
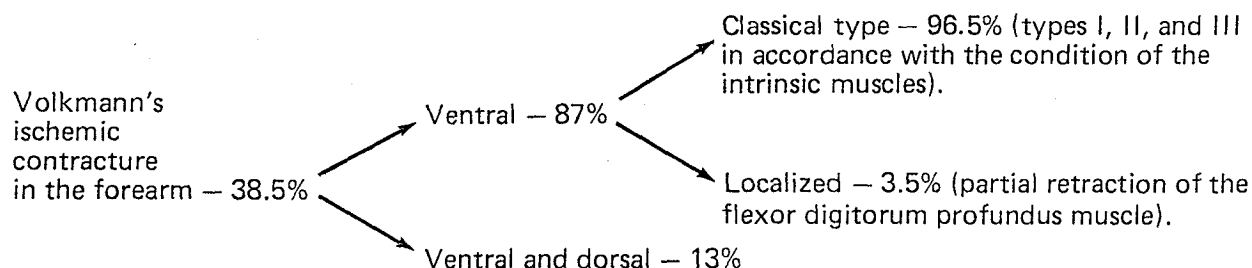
Pathology in the forearm and hand varies in accordance with the severity of the vascular deficit on

muscles and nerves, and this gives the final clinical picture. In the chart below, we have classified the different localizations of the muscular pathology based on the cases from our experience.

CLASSIFICATION OF ESTABLISHED VOLKMANN'S ISCHEMIC CONTRACTURE (CLASSICAL TYPE)

Many descriptions of the deformity of the classical muscular ischemia at the ventral part of the forearm have been published. In his first edition of *Surgery of the Hand* (1944) Bunnell³³ classified a hand *simple* or *severe* based on the characteristics of the deformity at

Localization of Muscular Ischemia of the Upper Limb Based on 83 cases



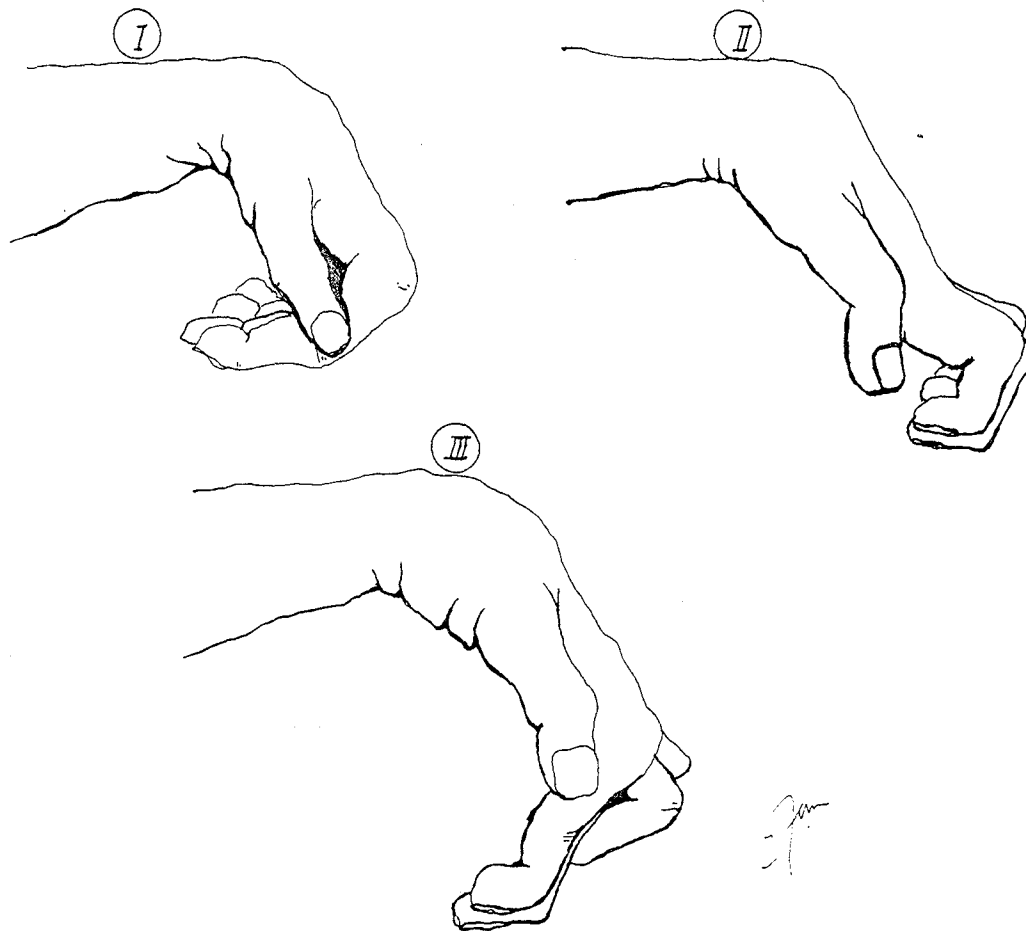


Fig. 10-1. Different types of established Volkmann's ischemic contracture. *Type I* with normal intrinsic muscles (simple digital "claw"). *Type II* with intrinsic paralysis at the fingers (intrinsic clawhand) and/or the thumb (opposition paralysis). *Type III* with intrinsic contracture of the interosseous and/or thumb muscles. In this drawing the radial side of the hand belongs to type III, and the ulnar side to type II (intrinsic clawhand).

the level of the forearm and hand. Pedemonte (1948),¹⁸⁴ a plastic surgeon from Uruguay, divided the deformity into two types, *the classic or favorable*, and *the useless hand*, depending on the possibilities of recovery with reconstructive surgery. Merle D'Aubigné (1955)¹⁶⁶ also divided the deformity into two types: (1) *without clawhand*, and (2) *with clawhand*. Seddon (1956)²⁰⁵ considered there to be three groups of the deformity in accordance with the extension and severity of the ischemia: *group I*, with diffuse ischemia, without infarct, and where spontaneous recovery occurs; *group II*, with typical muscular infarct and with or without nerve lesion; and *group III*, with diffuse fibrosis and severe paralysis and deformity.

Since 1959 we have classified the established period of the classical Volkmann's ischemic paraly-

sis or contracture into three types, based on the condition of the intrinsic muscles of the hand.²⁶³ We believe that the intrinsic condition of the hand is very important because, depending on the type of deformity, the surgeon obtains a very clear idea of the possible disorders of the nerves and muscles and which surgical program to apply. In type I deformities the intrinsic

Clinical Types of Volkmann's Ischemic Contractures

-
- Type I—normal intrinsic muscles
 - Type II—paralytic intrinsic muscles
 - Type III—retracted intrinsic muscles
 - Type IV—combined type
-

sic muscles are normal; in type II they are paralyzed; and in type III they are retracted because of ischemia. We may include a fourth group that represents a combination of the previous types (Figs. 10-1, and 10-2). We have employed this classification for nineteen years with great usefulness. Nerve reconstruction will not be discussed here.

Type I: Contracture of the Forearm Muscles With Normal Intrinsic Muscles (Simple "Claw" Deformity)

In this group the median and ulnar nerves are in good condition, and, in the majority of cases, this is the most simple condition to treat. The wrist and fingers are deformed in flexion, giving the picture of a simple "claw," and usually without joint stiffness (Fig. 10-5). In some patients the metacarpophalangeal joints may be in hyperextension in spite of normal intrinsic muscles, simulating an intrinsic paralysis clawhand. This deformity is produced during the attempt of finger extension and depends on a tenodesic effect produced by the long extensor tendon and the retention produced by the retracted long flexor digital muscles (Fig. 10-2, A and A').

In some cases of type I deformity, especially in children, even after the deformity has been corrected severe intrinsic dominances may result. This is a very difficult digital dysfunction to treat, and sometimes so difficult that one would prefer to deal with an intrinsic paralysis.

Type II: Contracture of the Forearm Muscles With Intrinsic Paralysis (Typical Intrinsic-Minus Clawhand and Opponens Paralysis)

In this type of deformity the intrinsic paralysis depends on the lesion of the median or ulnar nerves or both. Clawhand usually is severe because of the flexion position of the wrist and contracture of the long flexor muscles of the fingers (Fig. 10-6). In most favorable cases the intrinsic "claw" is *simple*, but in the majority of cases the contracture of the forearm muscles is associated with severe intrinsic paralysis

and complications at the digital joints (*complicated clawhand*). The most frequent complication is stiffness of the flexed interphalangeal joints while the metacarpophalangeal joints are stiff in extension (*totally rigid clawhand*). Another frequent complication at the middle joint is the stretching of the extensor mechanism produced by the permanent flexion position of the joints. Inability to extend the interphalangeal joint due to digital dysfunction is seldom seen, but we have had two cases in our experience (see classification of the intrinsic clawhand deformity in Chap. 5).

Paralysis of the intrinsic muscle of the thumb may depend on paralysis of the lateral and/or medial thenar muscles (Figs. 10-2, B and B', and 10-6).

In this group of established Volkmann's contracture with intrinsic paralysis there are frequent severe nerve lesions that complicate the surgical restoration of function of the hand because of sensory disturbances. Definitive median nerve lesion represents a severe impairment for hand function and deserves particular efforts for restoration.

Type III: Contracture of the Forearm Muscles With Intrinsic Contracture (Intrinsic-Plus Clawhand and Intrinsic-Plus Thumb)

Type III contracture is rare. The fingers are in the typical intrinsic muscle contracture because of retraction of the interosseous muscles. The metacarpophalangeal joints are in flexion and the proximal interphalangeal joints are in extension. The distal interphalangeal joint shows a marked flexion deformity due to contracture of the flexor digitorum profundus tendon (Fig. 10-2, C and D). The interosseous retraction is usually localized in the radial fingers. The wrist is also in flexion contracture. Intrinsic muscles of the thumb may also be contracted (Fig. 10-7).

Type IV: Combined Type

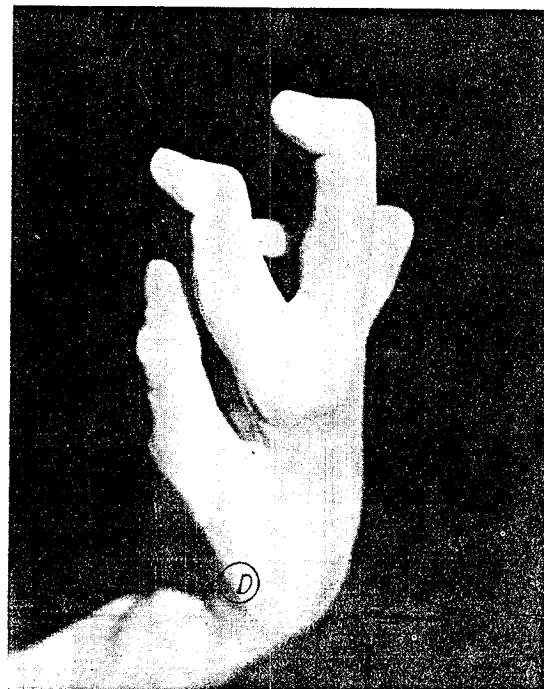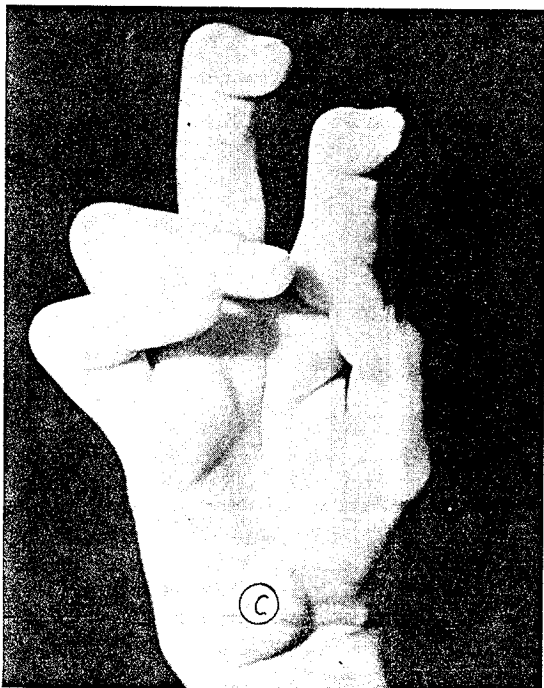
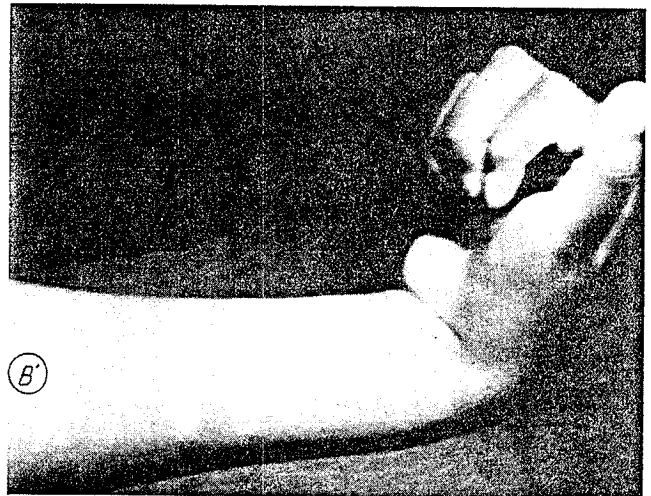
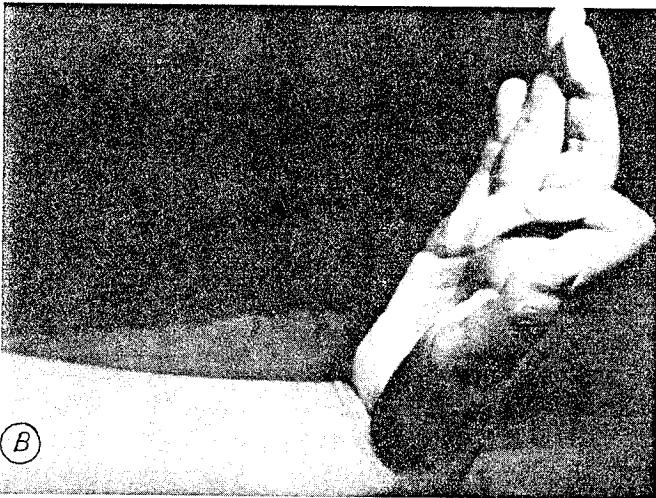
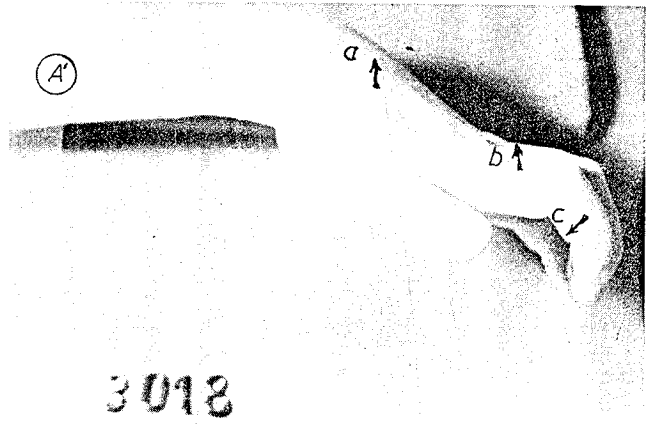
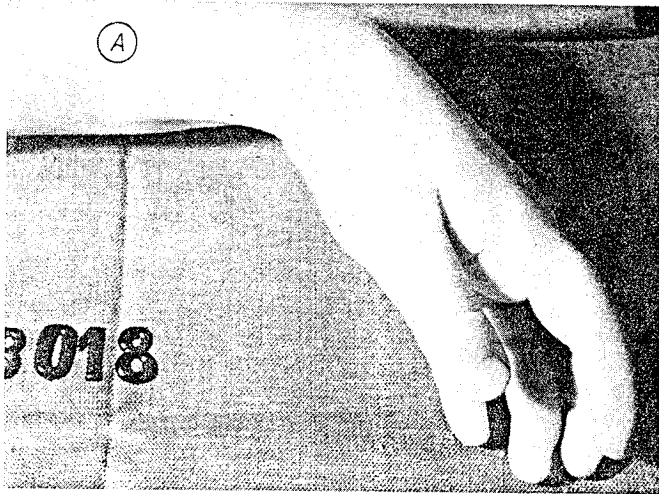
Often the types of deformity are combined, usually types I and II. Opposition paralysis may be com-

Fig. 10-2. A and A'. Type I contracture with mild retraction of the flexor muscles of the wrist and digits in a 10-year-old girl. The patient had the habit of extending the wrist (a) and metacarpophalangeal (b) to produce interphalangeal flexion by the passive effect of the retracted long flexor muscles (c) of the fingers (tenodesic effect).

B and B'. Volkmann's contracture with severe flexion contracture of the wrist. Intrinsic paralysis of the radial digits of the hand (type II) and complete extension of the

ulnar fingers (type I). Looking at the hand we have to suppose that the median nerve is damaged. Flexion of the fingers was good.

C and D. Volkmann's ischemic contracture with intrinsic paralysis at the ulnar side of the hand (type II) and Finocchietto's intrinsic retraction at the radial side (type III). The distal joints of the index and middle fingers are permanently flexed because of the retraction of their flexor digitorum profundus muscles at the forearm.



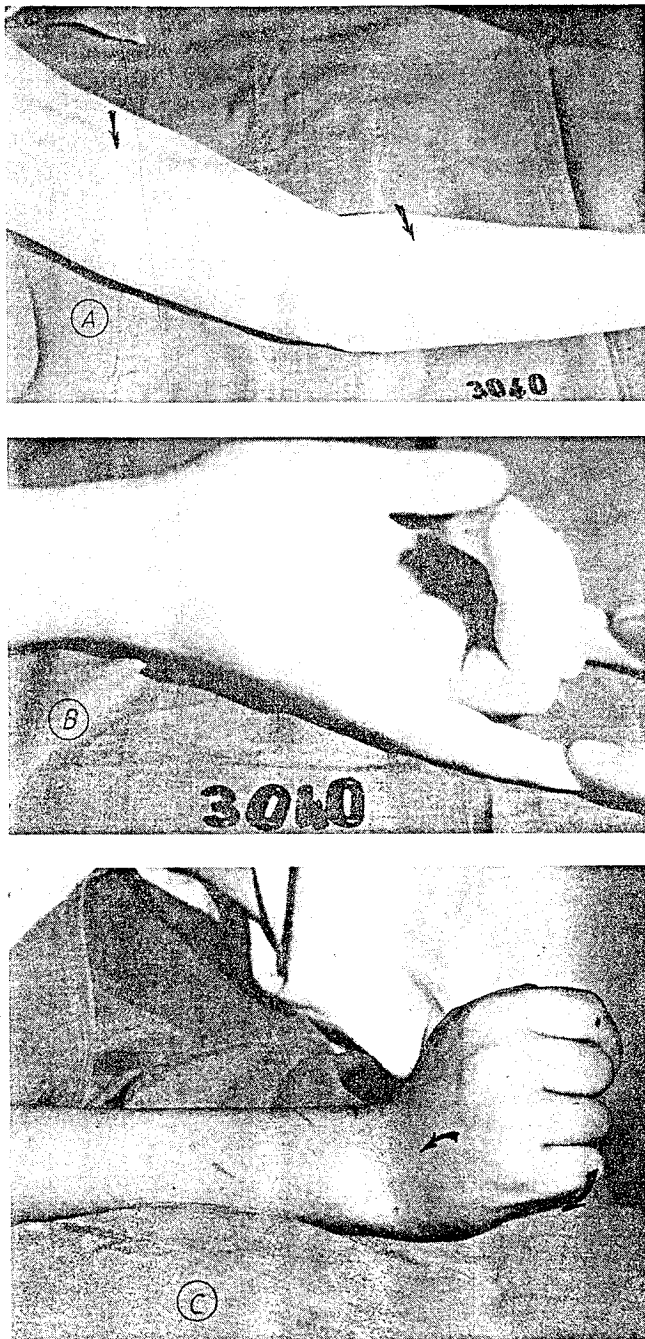


Fig. 10-3. These photographs show some peculiar situations in ischemic muscle contracture at the forearm.

A and B. Retraction of the flexor profundus muscles of the ring and middle fingers due to a severe injury at the level of the forearm and arm that produced a partial impairment of the circulation of the upper limb. It was impossible to extend passively the central fingers. This was corrected by tendinous lengthening (localized ventral Volkmann's ischemic contracture in the forearm).

C. Severe Volkmann's contracture of all the long flexor muscles of the digits and of the muscles of the dorsal compartment of the forearm. This combination produces permanent flexion of the digits with extension of the wrist. This represents a very difficult problem to resolve because there are very few muscles available to use as transfers (ventral and dorsal Volkmann's ischemic contracture in the forearm).

involves the radial fingers (3 cases; Fig. 10-2, C and D, and Fig. 10-7).

SIGNS OF THE DIFFERENT TYPES OF CONTRACTURE

Specific signs define each particular situation. In Volkmann's type I, extension of the fingers is obtained by increasing wrist flexion. In type II, the fingers actively tend to extend when the wrist is flexed and hyperextension of the proximal phalanx is prevented (Bouvier's maneuver). Interphalangeal extension is negative in some cases of interphalangeal complications of clawhand (see Chap. 5, Fig. 5-9). In Volkmann's type III, proximal interphalangeal flexion increases only after the metacarpophalangeal joints are passively flexed, as in all intrinsic contractures of the fingers. In these cases passive extension of the proximal phalanx increases hyperextension of the middle joint and flexion of the distal joint.

SURGICAL TREATMENT

Several clinical factors determine the choice of the most adequate surgical procedure: *type of digital deformity; deformation of carpal bones after growing period; functional condition and degree of retraction of the long digital flexor muscles; sensory impairment; clawhand complications; and thumb contracture.*

We shall consider the program of surgical treatment in accordance with the type of deformity or intrinsic muscular condition of the hand.

Type I

Type I deformities are the most favorable cases for correction of the deformity and restoration of hand
(Text continues on p. 323)

bined with normal interossei and lumbricals or intrinsic-minus clawhand with a normal thumb. Also, the paralytic clawhand may involve only some fingers while the others show normal intrinsic action as in Figure 10-2, B and B'. In general it is preferable to deal with the motor problem of an ulnar nerve "claw" than with a severe median nerve lesion which generally means a difficult problem for restoration of adequate sensibility. When types II and III are combined, the interosseous contracture usually

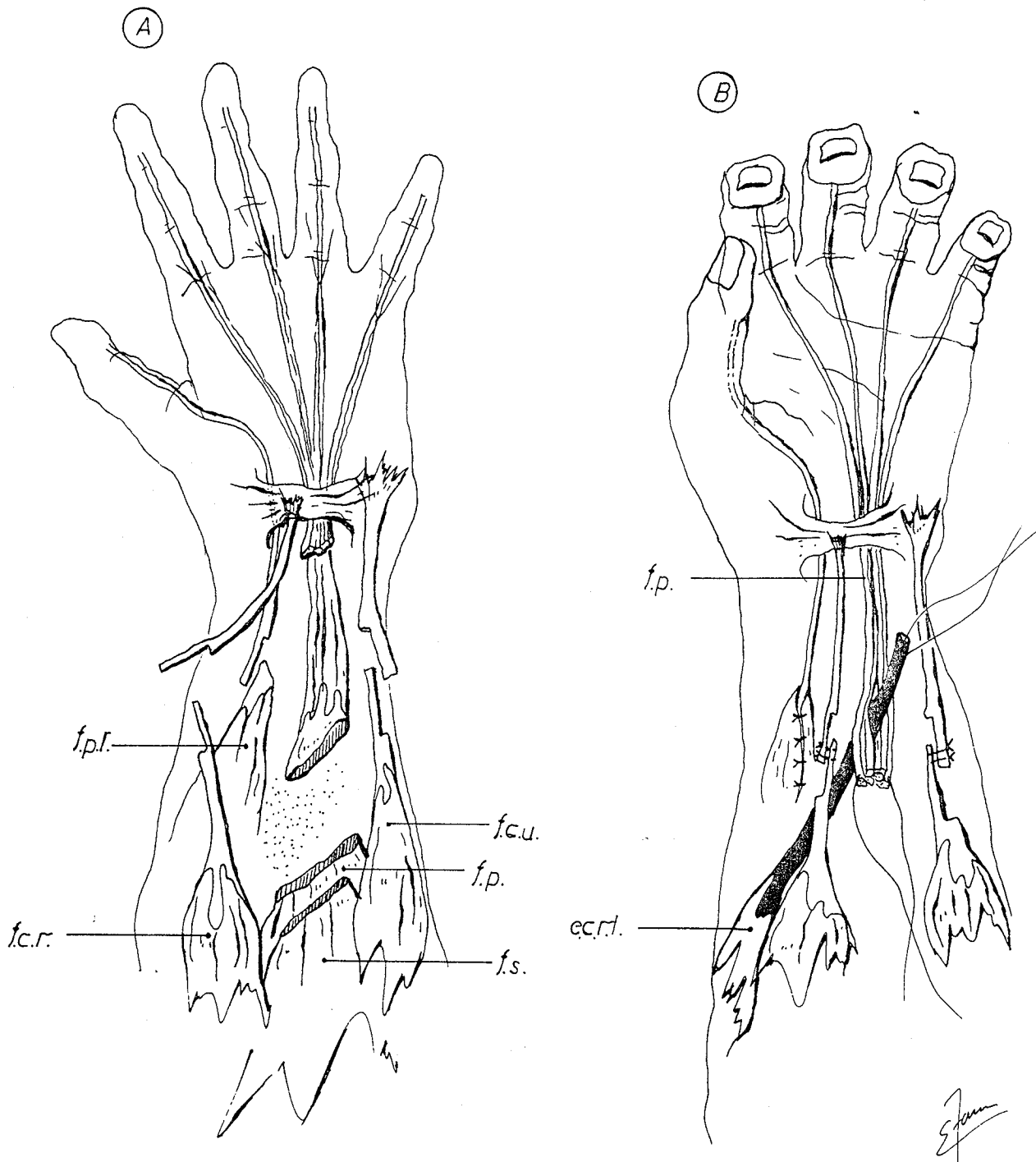


Fig. 10-4. These drawings represent the classical *excision-reconstruction procedure* to correct muscle ischemic contracture at the forearm.

A. *Excision of the fibrotic or infarcted profundus muscles of the forearm.* The size of the infarct may vary according to the severity of the circulatory impairment. Usually the principal damage is at the flexor digitorum profundus and the flexor pollicis longus. In the drawing the flexor carpi radialis (f.c.r.) and the flexor carpi ulnaris (f.c.u.) tendons have been lengthened, and also the flexor pollicis longus (f.p.l.). This basic program may be changed according to the particular condition of each patient.

B. *Reconstruction.* Repair of the lengthened tendons and transfer of the extensor carpi radialis longus (e.c.r.l.) to the distal stumps of the flexor digitorum profundus tendons (f.p.). Frequently during this muscular reconstruction the principal nerves, median and/or ulnar, are freed or repaired in cases of type II or type III deformities.

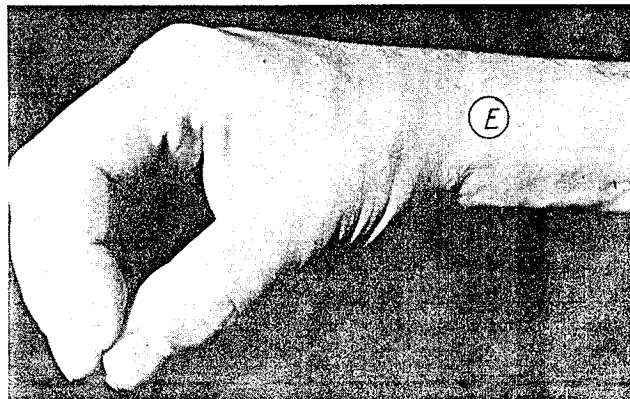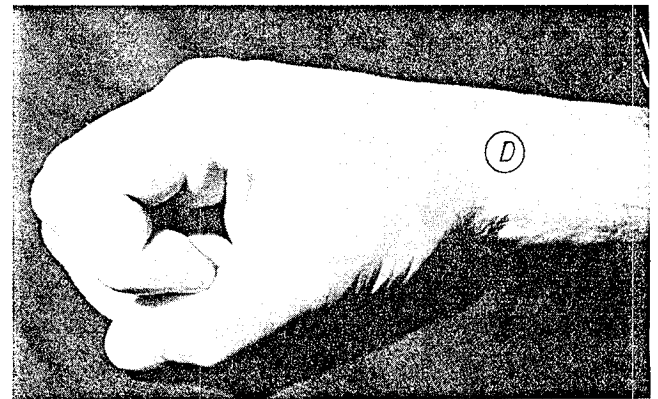
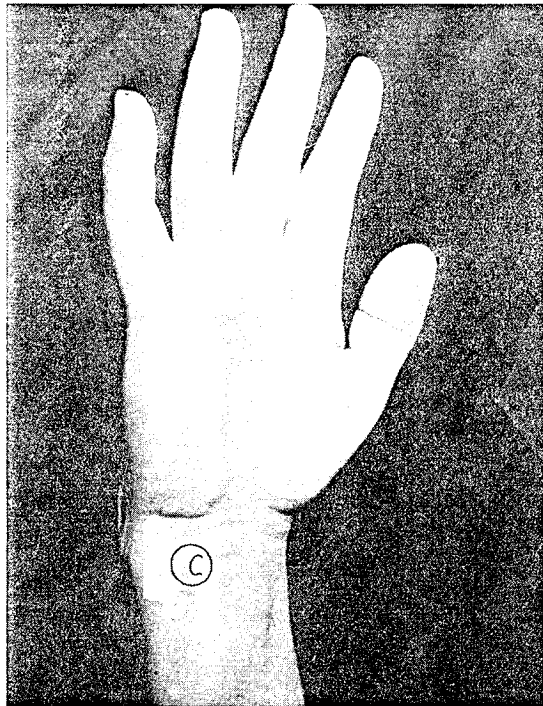

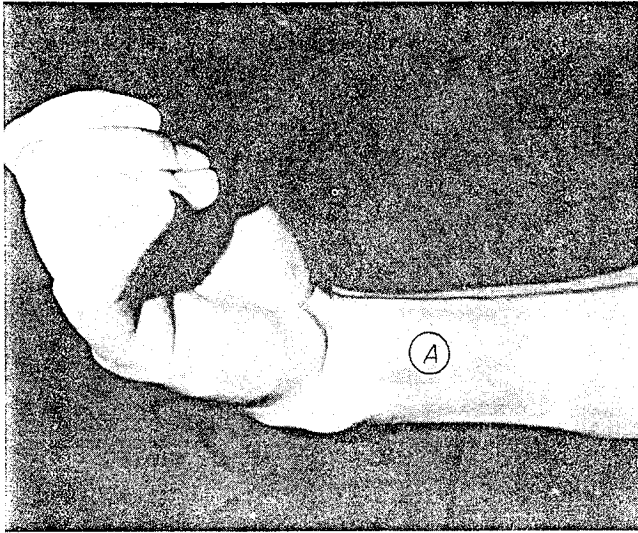


Fig. 10-5. A. Typical type I classical ventral Volkmann's ischemic contracture.

B. The muscular infarct was at the flexor digitorum profundus muscle (*a*). The median nerve (*b*) was included in scar tissue. The flexor superficialis was retracted but in very good functional condition. Due to this pathology the infarct was excised and the reconstruction was accomplished by the transfer of the flexor superficialis, which is divided at the level of the wrist, to the distal stump of the flexor digitorum profundus. This represents a "Z" lengthening between the flexor superficialis and flexor profundus digital tendons (intertendinous lengthening).²⁶²

C, D, and E. Functional result was good.

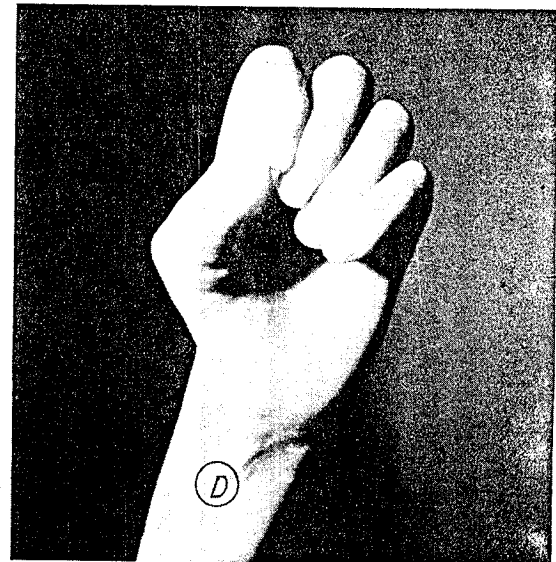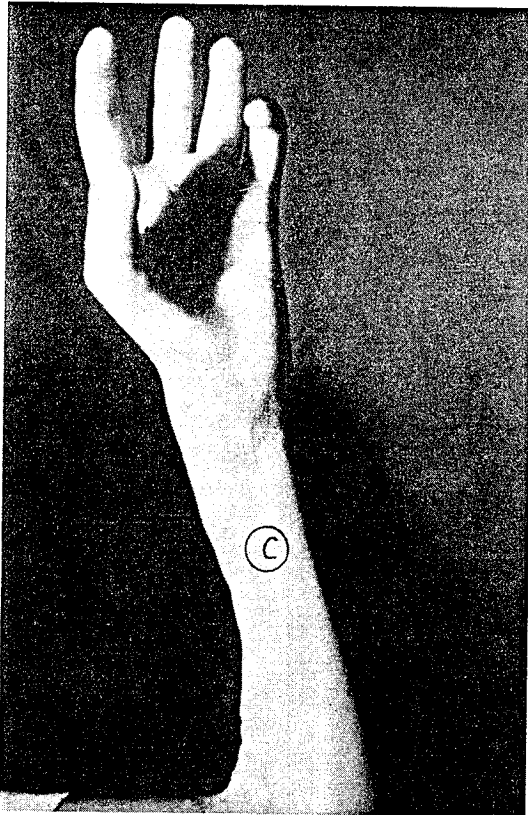
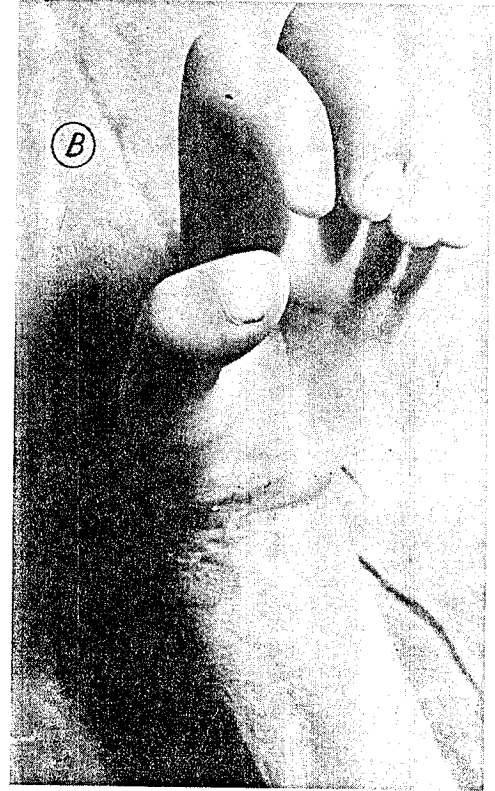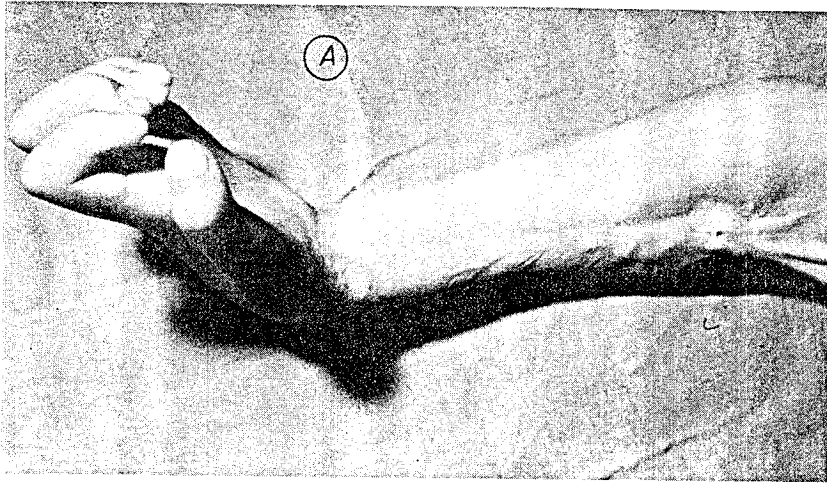


Fig. 10-6. A and B. Severe type II Volkmann's contracture of the radial and ulnar sides of the hand after a crush injury at the elbow and forearm. The fingers were in a marked intrinsic clawhand but still without joint complications.

C and D. Result after excision-reconstruction of the retracted muscles of the forearm according to the program described in the text and in Figure 10-4. The median and ulnar nerves were freed. Nerve release and correction of digital deformities should be early indications in severe ischemic contractures (evolutionary period).

During a second surgical stage the clawhand was corrected by a metacarpophalangeal capsuloplasty, and the opposition paralysis by an opponens transfer using the extensor indicis proprius tendon around the ulnar side of the wrist (see Chap. 6, Fig. 6-3).

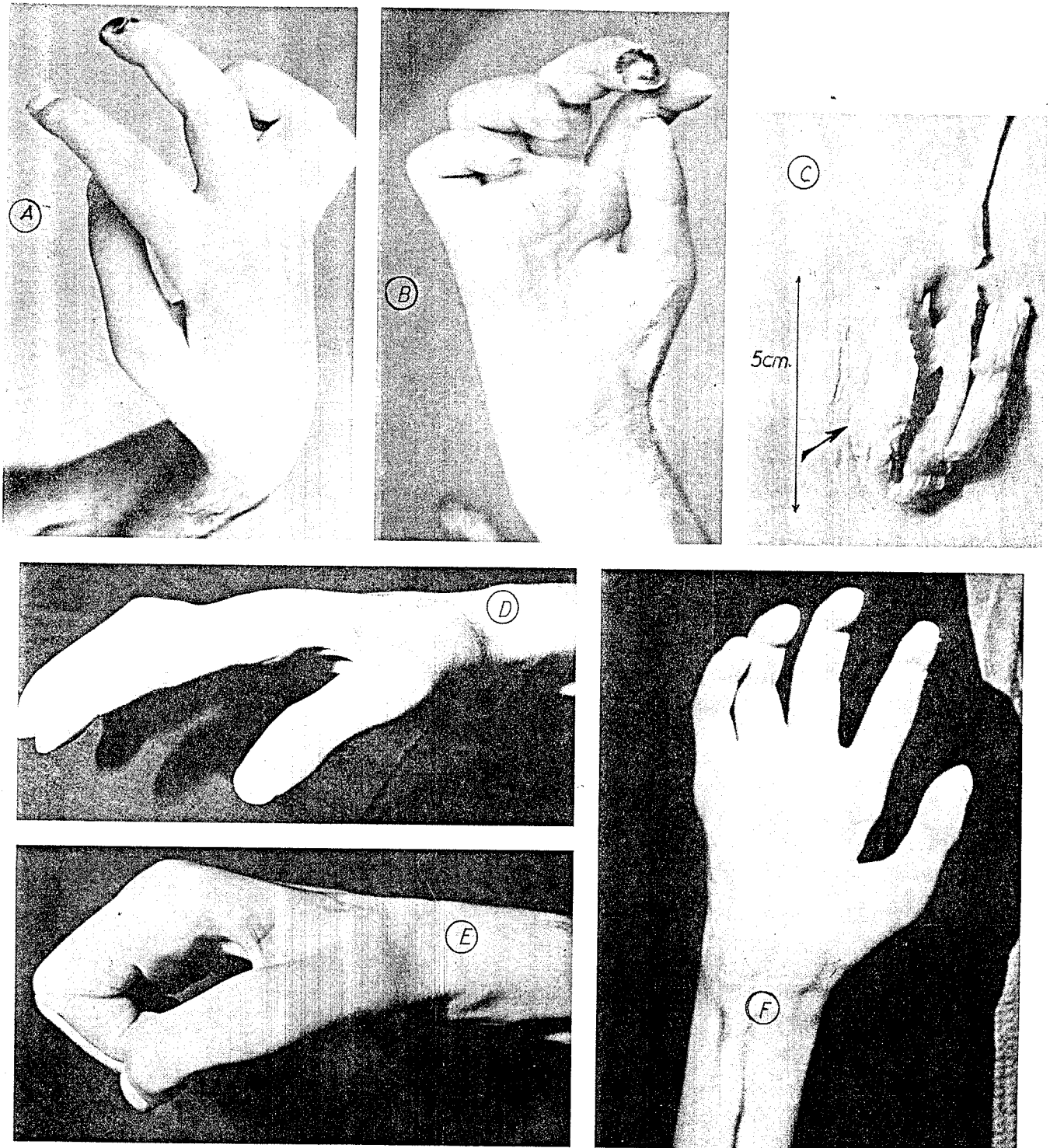


Fig. 10-7. A and B. Severe ischemic retraction after a compound fracture of the elbow. Intrinsic paralysis (claw-hand) at the ulnar fingers and intrinsic ischemic retraction at the radial side of the hand.

C. Six years after the accident, the muscular infarct 5 cm. in length was still present, without invasion of scar tissue.

D, E, and F. Result after excision-reconstruction at the forearm and simultaneous release of the retracted interosseous muscles of the index and middle fingers, adductor pollicis, and flexor pollicis brevis of the thumb. The first web was reconstructed by a rotatory flap (see Chaps. 6 and 9).

function, and this is due to the normal condition of the intrinsic muscles and normal cutaneous sensibility. All surgical correction is directed exclusively to the pathology at the forearm. The surgical procedure we prefer is the excision of the retracted infarcted or fibrotic muscles, and the functional reconstruction by tendon transfers and tendinous lengthening (excision-reconstruction procedure). The muscles to be used in the transfer need to be in good functional condition (grade 4) and preferably belong to the synergistic group. This method has been employed and developed by Parkes (1951)¹⁸² and Seddon (1956).²⁰⁵

The basic technique consists in "Z" lengthening of the principal flexor tendons of the wrist (flexor carpi radialis and ulnaris) and the flexor pollicis longus. When this last muscle is completely fibrotic or paralyzed it is sectioned and then activated by the transfer of the brachioradialis. The palmaris longus, retracted or paralyzed, is excised.

The flexor digitorum sublimis tendons are excised completely to the limit of the forearm incision. The tendons of the flexor digitorum profundus are partially excised at their musculotendinous junction, which avoids the retraction of the distal stump of the tendons into the carpal tunnel and permits their activation by tendon transfers. If the flexor tendons of the fingers are only divided, it is possible to observe partial recurrence of the deformity.

After the hand deformity is completely corrected the lengthened wrist flexor tendons are repaired. The extensor carpi radialis longus is transferred to the distal stumps of the flexor digitorum profundus tendons.

The described technique may vary in relation to different pathologic conditions. There are cases in which the flexor muscles of the wrist are not retracted. In severe pronation contractures it is necessary to excise the distal part of the pronator teres muscle. Occasionally the flexor superficialis muscles are partially retracted and with good voluntary contraction. In this situation their tendons are divided distally, above the wrist, and transferred to reinforce the reconstructed flexor profundus tendon. One of these tendons can be used to activate the flexor pollicis longus tendon.

We indicate the method of excision-reconstruction of the forearm when the following conditions are present: mild or severe retraction of the long flexor muscles; available muscles to be used as transfers; and moderate or no voluntary contraction in the finger flexor muscles after sufficient time for recovery.

In patients with types II and III of the deformity the forearm reconstruction must also be indicated after maximum spontaneous muscular recovery but before definitive articular stiffness of the fingers occurs. To save passive mobility of the joints of the fingers

is of fundamental importance in correction of Volkmann's contracture.

In our opinion the only indication for the classical muscle slide operation in this type of patient is when the flexion contracture of the digits is mild and the voluntary power of the flexor muscles is significantly preserved.

Occasionally we have employed an intertendinous lengthening between the flexor digitorum superficialis tendons and the flexor digitorum profundus tendons (Fig. 10-5).

Postoperative reeducation is very simple after the excision-reconstruction procedure because the extensor carpi radialis muscle is a synergist of finger flexion. The brachioradialis is a very efficient transfer to activate the flexor pollicis longus tendon.

It is interesting to point out that in some cases—particularly in children—the postoperative reeducation is not so simple due to the presence of different abnormal patterns of finger flexion. One of these habits, as previously mentioned, is the intrinsic dominance that produces an intrinsic-plus type of digital flexion and favors adhesions of the reconstructed long digital flexor tendons.

Another pathologic habit of digital flexion is the situation in which the patient flexes the interphalangeal joints by a tenodesic action with the long digital flexor tendons through wrist extension and hyperextension of the metacarpophalangeal joints. To break this abnormal pattern, a splint is used to maintain the wrist in neutral extension and the metacarpophalangeal joints in mild flexion, and full excursion of the transferred tendons is encouraged through correct movements.

Type II

In the group of patients with type II deformity, the intrinsic muscles depending on the median and/or the ulnar nerves are involved. The surgical program is divided into two surgical stages. During the first stage the retracted muscles of the forearm are corrected. As in type I deformity, excision-reconstruction is the operation we prefer. During the postoperative period finger reeducation is encouraged during several months and splinting is indicated to avoid the "claw" of the fingers.

The second surgical stage consists in the reconstruction of the intrinsic paralysis. The method employed depends on the possibility of available muscular motors to be employed as transfers and the type of deformity at the level of the fingers and thumb.

Clawhand, without important complications such as definitive joint stiffness or stretched extensor apparatus of the middle joints, is treated like any other

General Surgical Program in Established
Volkmann's Contracture

- Type I—Forearm excision-reconstruction
 Type II—*First stage:* forearm excision-reconstruction
 Second stage: intrinsic paralysis restoration
 Type III—Simultaneous forearm excision-reconstruction
 and intrinsic release
-

intrinsic paralysis by active or passive surgical procedures. The "lasso" operation and the metacarpophalangeal capsuloplasty (see Chap. 5) are the operations of our choice. If a motor is available—usually the brachioradialis—the indirect "lasso" technique is indicated. The muscular motor is prolonged with the distal stumps of flexor superficialis or tendon grafts, and these tendons are fixed at the vaginal ligament of the fibrous sheath of the flexor tendons of each finger. When no motors are available, metacarpophalangeal capsuloplasty with bony fixation is a good indication (Fig. 10-6). In cases of clawhand with definitive interphalangeal stiffness, joint fusion in functional position is indicated. If the metacarpophalangeal joints are also stiff, a capsulectomy or excision-arthroplasty with flexible implants is indicated, with simultaneous fusion of the proximal

interphalangeal joints. This is a very unfavorable situation to correct.

Paralysis of the intrinsic muscles of the thumb is preferably corrected by tendon transfers. The extensor indicis proprius around the ulnar of the wrist is an excellent motor to regain opposition in these cases. If there is a concomitant retropulsion deformity of the thumb, this must be corrected previous to or simultaneously with the opponens transfer (see Chap. 6).

Type III

In the patient with type III deformity the *contracture of the muscle of the forearm and of the intrinsic muscles must be corrected during the same surgical procedure*. It would be impossible to obtain digital function with contracted intrinsic muscles.

The technique of the operation to release the interossei depends on the severity of the contracture. In mild cases the classical technique of intrinsic lateral bands and triangular interosseous laminae excision (*distal intrinsic release*) is indicated; but in cases with flexion contracture of the metacarpophalangeal joints the interosseous tendons are excised at the level of the neck of the metacarpal bones (*proximal intrinsic release*). These techniques have been described in Chapter 9.